



Middle column Stent-screw Assisted Internal Fixation (SAIF): a modified minimally-invasive approach to rescue vertebral middle column re-fractures

Fortunato Di Caterino ¹, Eva Koetsier,^{2,3} Joshua A Hirsch ⁴, Maurizio Isalberti,⁵ Diego San Millan,⁶ Francesco Marchi,⁷ Luigi La Barbera,^{8,9} Marco Pileggi,⁵ Alessandro Cianfoni^{5,10}

For numbered affiliations see end of article.

Correspondence to

Dr Fortunato Di Caterino, Department of Interventional Neuroradiology, University Hospital Centre Besancon, Besancon, 25030, France; dr.fortunatodicaterino@gmail.com

Received 13 October 2022

Accepted 26 December 2022

ABSTRACT

Background There is limited literature regarding the re-fracture of a previously augmented vertebral compression fracture (VCF). These re-fractures may present as an asymptomatic remodeling of the vertebral body around the cement cast while in other cases they involve the middle column, at the transition zone between the cement-augmented and non-augmented vertebral body.

In the latter, a posterior wall retropulsion is possible and, if left untreated, might progress to vertebral body splitting, central canal stenosis, and kyphotic deformity. There is no consensus regarding the best treatment for these re-fractures. There are cases in which a repeated augmentation relieves the pain, but this is considered an undertreatment in cases with middle column involvement, posterior wall retropulsion, and kyphosis.

Methods We report four cases of re-fracture with middle column collapse of a previously augmented VCF, treated with the stent-screw assisted internal fixation (SAIF) technique. A modified more postero-medial deployment of the anterior metallic implants was applied, to target the middle column fracture. This modified SAIF allowed the reduction and stabilization of the middle column collapse as well as the partial correction of the posterior wall retropulsion and kyphosis.

Results Complete relief of back pain with stable clinical and radiographic findings at follow-up was obtained in all cases.

Conclusions In selected cases, the middle column SAIF technique is safe and effective for the treatment of the re-fracture with middle column collapse of a previously cement-augmented VCF. This technique requires precision in trocar placement and could represent a useful addition to the technical armamentarium for VCF treatment.

WHAT IS ALREADY KNOWN ON THIS TOPIC

⇒ The re-fracture of a previously augmented vertebral compression fracture (VCF) poses a management challenge, and there is no consensus on the optimal treatment.

WHAT THIS STUDY ADDS

⇒ A modified stent-screw assisted internal fixation (SAIF) technique was able to rescue vertebral middle column re-fractures in previously augmented VCF, with satisfactory radiologic and clinical results

HOW THIS STUDY MIGHT AFFECT RESEARCH, PRACTICE OR POLICY

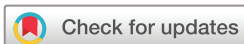⇒ This report raises awareness of the biomechanical implications of middle column re-fractures in augmented vertebrae and suggests a minimally-invasive rescue treatment alternative to more invasive surgical techniques.

the vertebral body around the cement cast, with a subsidence of non-augmented portions of trabecular bone.⁷ A more prominent collapse can occur with involvement of the middle column, at the transition zone between a cement-augmented and non-augmented vertebral body.⁸ Such re-fractures can be characterized by posterior wall retropulsion and focal kyphosis, present with recurrent back pain and signs of central canal compromise. If left untreated, these might progress to splitting between augmented and non-augmented portions of the vertebral body, further increasing central canal stenosis and kyphotic deformity (figure 1).

Treatment of these re-fractures is challenging. While some cases can be treated with repeated augmentation,^{6,9} in cases with re-fracture of the middle column, posterior wall retropulsion and kyphosis, simple augmentation is considered an undertreatment and salvage by surgical spinal fixation is advocated.^{8,10} Nevertheless, surgical fixation is invasive and may be associated with morbidity and risk of hardware failure, especially in elderly patients with poor bone quality.¹¹ A minimally-invasive, yet efficient, option would be desirable in this fragile patient population.

INTRODUCTION

Vertebral augmentation (VA) is a widely used procedure with the intent of pain palliation and stabilization of vertebral compression fractures (VCFs) due to trauma, osteoporosis, and tumors.^{1,2} Following an osteoporotic VCF, the event of a new VCF, at adjacent or remote levels, has been thoroughly investigated, with a reported incidence ranging from 12–52%.³ Less known, and less frequently reported, is the event of re-fracture of a VCF that has been submitted to VA.^{4–6} These re-fractures can simply be a typically asymptomatic re-modelling of



© Author(s) (or their employer(s)) 2023. No commercial re-use. See rights and permissions. Published by BMJ.

To cite: Di Caterino F, Koetsier E, Hirsch JA, et al. *J NeuroIntervent Surg* Epub ahead of print: [please include Day Month Year]. doi:10.1136/jnis-2022-019752

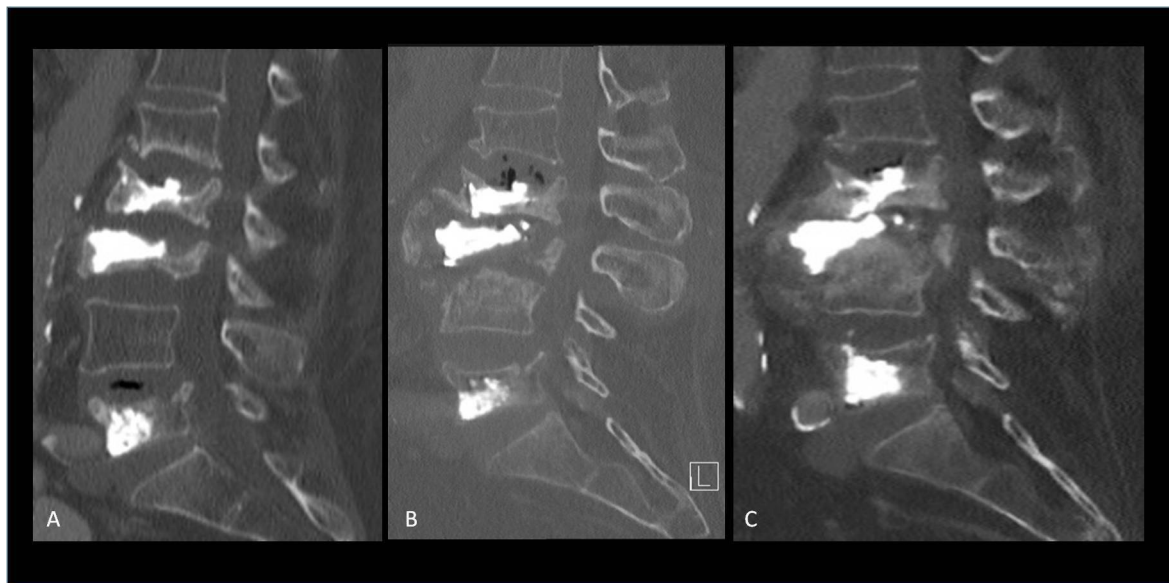


Figure 1 Post-augmentation middle column re-fracture managed conservatively. (A) CT scan post-vertebroplasty of L2, L3 and L5 for multiple osteoporotic vertebral body fractures. The middle column of L3 is collapsed and non-augmented (A). The patient reported early pain recurrence, and at 3 months follow-up there was L3 re-fracture, with splitting between the augmented anterior column and the non-augmented middle column (B); a new fracture of L4 and mild re-fracture of L2 are also visible. Follow-up at 12 months showed L2–L4 ankylosis, with further splitting, posterior wall retropulsion, hyperkyphosis, and central canal stenosis (C). The patient complained of chronic severe low back pain and neurogenic claudication.

We report four cases of re-fracture with middle column collapse of a previously augmented VCF, that were treated with a minimally-invasive percutaneous image-guided technique, called stent-screw assisted internal fixation (SAIF), using a modified, more postero-medial deployment of the anterior metallic implants, to target the middle column fracture. Modified SAIF allowed reduction and stabilization of the middle column collapse, partial correction of the posterior wall retropulsion and kyphosis, through the combined use of vertebral body stents (VBS) (DePuySynthes-Johnson & Johnson, USA) and fenestrated pedicle screws (injection pin, 2B1, Italy). This intervention, that can be called ‘middle column SAIF’, was considered a middle column re-fracture rescue procedure.

In all four cases the patient’s back pain was relieved with stable clinical and radiographic findings at follow-up.

PROCEDURE TECHNIQUE

In the type of re-fractures addressed in this case series the middle column is the target of the treatment, and the anterior column is usually already cement-augmented and thus not accessible. The aim of the treatment is to reduce the middle column collapse, thereby correcting posterior wall retropulsion and kyphosis, to augment it with cement, and to finally create a rigid bridge for internal fixation between anterior and posterior columns to avoid splitting.

The percutaneous SAIF technique, as described previously in detail,¹ is performed with the patient under general anesthesia and under fluoroscopic guidance. It entails bilateral transpedicular insertion of balloon-mounted VBS (DePuySynthes-Johnson & Johnson) in the vertebral body, followed by insertion of fenestrated cannulated percutaneous pedicle screws (injection pin, 2B1) into the stents culminating with cement augmentation solidifying the construct. Concomitant adjacent vertebroplasty is performed to treat milder VCFs (non-vertebra plana fracture, ie, with a minor degree of collapse) or with prophylactic intent when considered appropriate per institutional protocol.^{1,12}

The patients were positioned prone on the fluoroscopic table, and bolsters were placed under the abdomen and chest to obtain postural adjustments that may contribute to passive fracture reduction. Intravenous antibiotic prophylaxis was administered.

In one case intraoperative myelography was utilized to monitor the position of the posterior wall during expansion of the VBS. The collapse of the middle column required a modified approach, via a far-oblique bilateral trans-pedicular or an extra-pedicular trocar access, in order to insert and deploy small-sized VBS in the posterior half of the vertebral body, toward the midline.

The stents were carefully expanded with a pre-mounted balloon with the aim of obtaining a satisfactory reduction of the fracture, vertebral body height restoration and, whenever possible, partial correction of the posterior wall retropulsion.¹³ Whenever possible, stents were positioned with the long axis parallel to the vertebral endplates, to ensure that the radial force is applied in cranio-caudal direction as much as possible. Transpedicular screws were subsequently inserted via a k-wire exchange in the stent’s lumen and high viscosity polymethyl methacrylate (PMMA) cement (Vertaplex HV, Stryker, Kalamazoo, MI) was injected through the screws in the stents.

CASE 1

A patient in their 70s with severe osteoporosis presented with VCF of L2 and was treated with stent kyphoplasty of L2 and prophylactic VA of L1 and L3 (figure 2A). The patient reported back pain relief in the first days following the procedure.

Four months later, due to recurrent severe low back pain, plain films and CT scan were performed, showing a collapse of the L3 middle column and a wedge fracture of L4 (figure 2B).

The patient was treated with a middle column SAIF procedure through bilateral transpedicular stenting (small size VBS, 13 mm in length × 15 mm in diameter) deployed in the posterior part of the vertebral body of L3, and transpedicular screws (figure 2D–H). A vertebroplasty of L4 and prophylactic

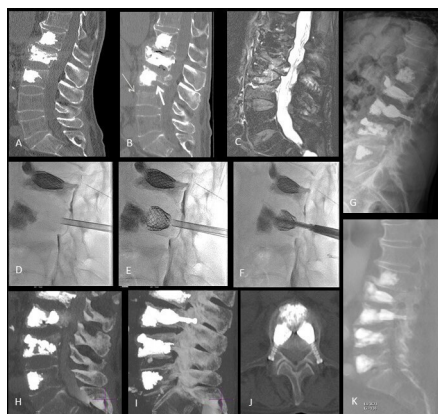


Figure 2 Patient 1. (A) CT scan after stent kyphoplasty of L2 and augmentation of L1 and L3. (B–C) CT scan and MRI at 4 months follow-up showing a collapse of the L3 middle column (thick arrow on B), with posterior wall retropulsion, and a wedge fracture of L4 (thin arrow on B). (D–F) Procedural fluoroscopic lateral views of the modified stent-screw assisted internal fixation (SAIF) of L3: under intraoperative myelography, 4.5 mm bilateral transpedicular trocars are inserted (D), small-size vertebral body stents are inserted and balloon-expanded in the posterior part of the vertebral body (E), and over a k-wire cannulated fenestrated screws are inserted and bone cement is injected (F). (G–J) Post-procedure imaging documentation, with standing plain films (G) and sub-volume maximum intensity projection CT images (H–J), showing partial height restoration of the middle column collapse, and bridging across the middle column and pedicles with the screw-stent-cement complex. (K) Sub-volume sagittal reformatted CT scan at 4 years follow-up, showing stable results at L3, with interval partial compression fracture of L5, which remained asymptomatic.

augmentation of L5 were also performed, under general anesthesia. Intraoperative myelography was performed, showing no further canal encroachment during stent expansion.

At 1 month follow-up the patient had significant pain reduction, but 3 months later the patient needed an additional vertebral augmentation due to painful mild re-fracture of L4, with complete pain resolution at subsequent 1-month and 6-month follow-up. Radiological stable results at L3 were documented on CT scan performed for aortic pathology 4 years later (figure 2K).

CASE 2

A patient in their 80s with known osteoporosis presented with a non-traumatic VCF of L1, characterized by a large osteonecrotic cleft in the vertebral body (figure 3A). The patient was treated with a vertebroplasty of L1, through bilateral pedicular access (figure 3B), but 2 weeks later reported recurrent severe back pain at the thoraco-lumbar junction. Plain films and CT scan showed middle column re-fracture at L1 and a new VCF of T12, with local kyphotic deformity (figure 3C–D). The patient was treated with an L1 middle column SAIF procedure with transpedicular bilateral access, with two VBS (small size VBS, 13 mm in length × 15 mm in diameter) in the posterior third of the vertebral body and transpedicular screws, SAIF on the vertebral body of T12 and prophylactic vertebroplasty of T11 and L2, under general anesthesia. Post-procedure imaging showed a successful height restoration and partial kyphosis correction (figure 3G–I).

Six months later the patient was asymptomatic, and imaging showed stable findings (figure 3K). The clinical condition of the patient remained stable up to 12-month follow-up.

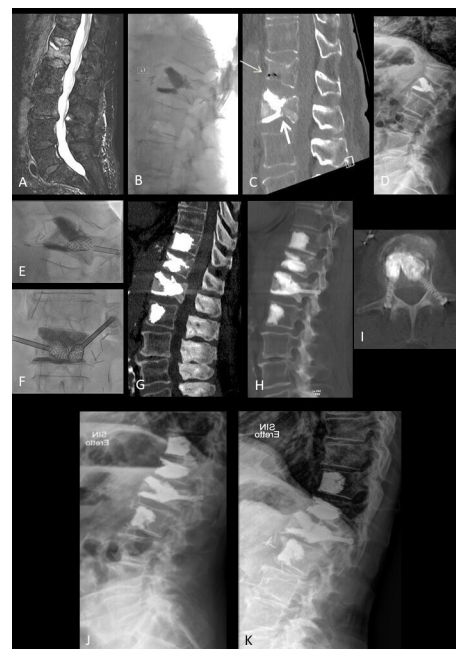

Figure 3 Patient 2. (A) T2-weighted fat-suppressed MRI showing fracture of L1 with bone marrow edema and large osteonecrotic cleft in the vertebral body, subsequently treated with vertebral augmentation (B). (C–D) CT scan and standing plain film 2 weeks later showing middle column collapse at L1 (thick arrow on C) and a new fracture of T12 (thin arrow on C), with local kyphotic deformity (D). (E–F) Procedural fluoroscopic orthogonal views of the modified stent-screw assisted internal fixation (SAIF) of L1: 4.5 mm bilateral transpedicular trocars and small-size vertebral body stents are inserted and balloon expanded in the posterior part of the vertebral body. (G–I) Post-procedure CT scan showing reconstruction of L1 middle column with modified SAIF technique, vertebral body stent expansion and partial fracture reduction of T12 and prophylactic augmentation of T11 and L2. Standing plain films showing stable result at 1-month (J) and 6-month (K) follow-up, respectively.

CASE 3

A patient in their 80s, obese and with multiple comorbidities, presented with an acute osteoporotic VCF of L1 after a minor trauma and chronic VCFs of L2 and L4 (figure 4A). Eleven days after the trauma the patient was treated with a vertebroplasty of L1 (bilateral transpedicular access) and a prophylactic augmentation of T12 (unilateral extrapedicular access) under local anesthesia. A good cement-filling of L1 was obtained (figure 4B), both in the trabecular bone and in a large anterior cleft. The patient reported early satisfactory pain control, but already 7 days after the procedure the patient experienced spontaneous recurrence and worsening of back pain without radicular irradiation or neurological deficits.

A CT scan demonstrated a re-fracture of the middle column of L1 with posterior wall retropulsion (figure 4C–D) and focal kyphotic deformity at the thoraco-lumbar junction. Two weeks after the vertebroplasty, a middle column SAIF was performed under general anesthesia (figure 4E–H). Due to an unfavorable access angle between pedicles and collapsed posterior half of the vertebral body, a bilateral extra-pedicular access was undertaken to deploy two VBS (small size VBS, 13 mm in length × 15 mm in diameter) in the posterior part of the vertebral body until good reduction of the fracture was achieved. Afterwards two pedicle screws were inserted in the stents with trans-pedicular access to anchor the stent and serve as a bridge. Finally, PMMA

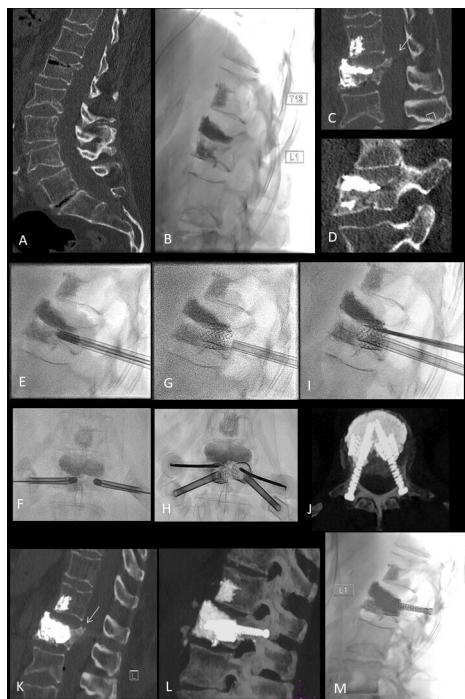


Figure 4 Patient 3. (A) CT scan showing fracture of L1 with air-filled cleft and chronic fracture of L2 and L4. (B) Lateral fluoroscopic view after vertebroplasty of L1 with good cement-filling both in the trabecular bone and in a large anterior cleft; prophylactic augmentation of T12. (C–D) CT scan 7 days later showing re-fracture of the middle column of L1 with posterior wall retropulsion (arrow on C). (E–I) Procedural fluoroscopic views of the modified stent-screw assisted internal fixation (SAIF) of L1: 4.5 mm bilateral trocars are inserted with extra-pedicular access (E–F), and small-size vertebral body stents are inserted and balloon-expanded in the posterior part of the vertebral body (G). Trans-pedicular access is then performed with 14G cannulas, exchanged with a k-wire to insert the fenestrated trans-pedicular screws into the stents' lumen. (K–L) Post-SAIF CT scan showing height restoration of the middle column collapse, bridging across the middle column and pedicles with the screw-stent-cement complex and partial correction of the posterior wall retropulsion (arrow in K). (M) Standing plain film at 4 years follow-up showing stable result.

was injected to fill the stent cavities and to link the stents with the screws. On stand-up plain films a partial correction of the kyphosis was observed, while a CT scan showed satisfactory restoration of the middle column height and partial correction of the posterior wall retropulsion (figure 4K–L). The last follow-up, at 4 years, demonstrated stable clinical conditions and radiographic findings (figure 4M).

CASE 4

A patient in their 80s presented with a painful spontaneous VCF of L4 (figure 5A–B) at the level of a previously radiated renal cell carcinoma vertebral metastasis. The patient was treated with bilateral transpedicular vertebroplasty with apparently satisfactory cement filling of the vertebral body on fluoroscopic images (figure 5C–D), providing full pain relief. Concurrent biopsy showed no recurrent tumor. After a pain-free interval following vertebroplasty, the patient presented with recurrence of pain. The patient sought clinical attention 25 days after the initial treatment. A CT scan demonstrated incomplete cement distribution in the center of the vertebral body leaving the entire middle column bare of cement (figure 5E). In addition, there

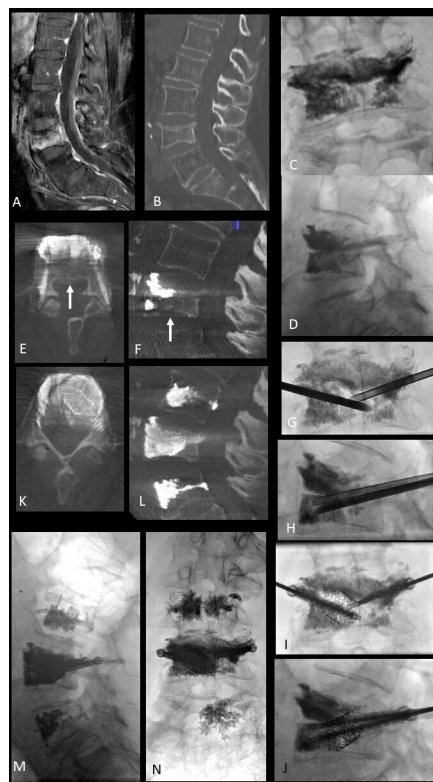


Figure 5 Patient 4. (A–B) MRI (contrast-enhanced fat-saturation T1) and CT scan showing fracture of superior endplate of L4, with bone marrow edema. (C–D) Fluoroscopic views after vertebroplasty of L4, performed with bilateral pedicular approach, with apparent good cement-filling. (E–F) CT scan obtained 25 days postoperatively due to pain recurrence, showing U-shaped distribution of cement and large 'bare area' in the center of the vertebral body and middle column (arrow on E), and a new coronal split fracture of inferior endplate, coursing along the junction between the anterior and middle column (arrow on F). (G–J) Procedural fluoroscopic views of transpedicular middle column stent-screw assisted internal fixation (SAIF) with left unilateral stent and bilateral transpedicular screws. Post-procedure flat panel CT (K–L) and 3 month follow-up upright fluoroscopic views (M–N) showing fracture reduction and bridging with the stent-screws-cement complex at L4.

was a new inferior endplate fracture with incomplete coronal split between the anterior and middle columns and subsidence of the superior endplate (figure 5F). A middle column SAIF was performed under general anesthesia, unilaterally, on the left side, with a small-sized stent and a 5 mm × 46 mm screw; on the right side there was insufficient space for deploying a VBS, and a transpedicular 5 mm × 37 mm screw was placed (figure 5G–H). Prophylactic vertebroplasty of L3 and L5 was performed. An immediate postoperative flat-panel CT was performed in the angio-suite showing protection of the middle column, filling of the bare area by the stent and cement, and reduction of the inferior endplate fracture (figure 5I–J). Follow-up upright fluoroscopic images at 3 months showed stable anatomical restoration of the L4 vertebral body (figure 5M–N).

DISCUSSION

This report describes four cases of re-fracture, with middle column collapse, of previously cement-augmented VCFs which were successfully treated in two European centers with a modified approach of the previously reported SAIF

technique, here called middle column SAIF. Literature regarding new fractures involving a previously cement-augmented VCF, indicated in this series as re-fractures, is limited. The incidence rate of re-fractures is reported within an extremely scattered and wide range (from 0.56–63%),^{6,14} possibly due to lack of precise definition criteria and heterogeneity in follow-up practices. It is still unclear whether these re-fractures are procedure-related,^{6,15,16} part of the natural course of osteoporosis,¹⁴ or due to the biomechanics of the VCF and/or due to an insufficient stabilization effect achieved by suboptimal vertebral augmentation (ie, incomplete or partial cement filling). In addition, there is no consensus regarding the optimized treatment of these re-fractures.

The re-fracture may represent subsidence of non-augmented portions of vertebral body⁷ around the cement cast, with mild secondary vertebral height loss, which is typically asymptomatic, and is therefore usually incidentally found at radiological follow-up.¹⁴ In some cases, the re-fracture features a greater secondary collapse, and is more frequently symptomatic, presenting as pain recurrence.⁶ Much less frequently reported is the re-fracture of the non-augmented middle column, at the junction with the augmented anterior column⁸ with potentially catastrophic consequences, due to posterior wall retropulsion, coronal splitting of the vertebral body, kyphotic deformity, and instability. In standard vertebral augmentation, performed with vertebroplasty or balloon kyphoplasty, cement is usually distributed in the anterior two thirds of the vertebral body (the anterior column), while the posterior third of the vertebral body (middle column) is left, at least to some extent, non-augmented, either due to the geometry of the oblique trans-pedicular needle access or intentionally to avoid cement leakage into the epidural space.¹⁷ This results in a non-reinforced ‘bare area’¹⁸ across the middle column. Among spinal interventionalists, augmentation and reinforcement of the anterior column is usually considered more important than that of the middle column. In addition, results from biomechanical finite element models (FEM) suggest that re-fracture of the middle column in a previously augmented vertebra could be further explained by the high strain gradient across the augmented anterior column and the weaker unprotected middle column, leading to local strain intensification effects.¹⁹ The osteoporotic lumbar spine model demonstrated that the SAIF technique is more effective than standard VA in significantly reducing the median strain distribution across the middle column both in standing and during upper body flexion, especially on the superior endplate and on the posterior wall.¹⁹ The promising results predicted by the biomechanical models seem to be confirmed in a subsequent series of 80 severe osteoporotic VCFs treated with SAIF, where mild re-fracture/subsidence of treated vertebrae was observed in 20% of cases, but no severe re-fractures occurred, and no patients required re-intervention or surgical salvage.²⁰ The fracture pattern, avoiding collapse and splitting of the middle column as observed following VA, can be related to the biomechanical role of the screws anchoring the stent-cement complex to the posterior lamina, acting as a stiff bridge across the middle column.¹⁹

An additional potential factor at the base of the middle column re-fractures suggested by the biomechanical models might be the higher load transfer to the stiff anterior column in upper body flexion,¹⁹ which may shield the mechanical stimulus on the

middle column and lead to bone resorption. This latter mechanism would likely require a rather longer time to develop (from 4 months up to 2 years),²¹ but in the current series re-fractures occurred within shorter times from VCF augmentation (from 2 weeks up to 4 months), which is a time frame more compatible with vertebral bone disruption and subsidence around the cement cast, as reported after simple augmentation by Nagaraja *et al.*⁷

In case 1 the middle column fracture occurred in a vertebra which had previously undergone vertebral augmentation with prophylactic intent.

The role of prophylactic vertebral augmentation remains controversial, and differences in strategy exist, especially between the USA and Europe. Even though a significant reduction in VCF of adjacent vertebrae receiving prophylactic augmentation has been reported,^{12,22} high level evidence supporting improved patient outcome remains to be determined.

In the European centers that contributed patients to this series, adjacent level vertebroplasty is performed prophylactically when deemed appropriate per institutional protocol, in particular for osteoporotic fractures at the thoraco-lumbar junctional level and/or with kyphotic deformity.^{1,12,23}

In case 1, it is unclear whether prophylactic augmentation favored the middle column fracture or whether it instead protected the anterior column, thus avoiding a complete vertebral body collapse. In symptomatic re-fractures, repeating and completing the vertebral augmentation effectively relieves pain.^{6,9} However, in the case of a middle-column collapse following cement augmentation, repeat augmentation alone cannot provide fracture reduction nor canal decompression. In addition to increasing the risk of epidural cement leakage, it may in fact represent an undertreatment.

Surgical solutions have been advocated in severe re-fractures following vertebral augmentation, but consensus or strong evidence are lacking to support which surgical approach to adopt. Nagoshi *et al.*²⁴ described the treatment of three cases of severe re-fracture of augmented vertebrae by anterior spinal fixation alone, with long-term pain relief but with progression of kyphotic deformity. Yang *et al.*²⁵ reported a series of 22 re-fractures after vertebroplasty, in which a combination of anterior and posterior surgery was necessary in 68% of cases. Surgical approaches for these middle column re-fractures imply a high degree of invasiveness and carry a substantial morbidity risk, especially in elderly patients with scarce bone quality.¹¹ Recent studies described the insertion of transpedicular screws after balloon kyphoplasty,^{26,27} but these did not specifically address the middle column fracture, and due to deflation effect could not provide a substantial vertebral height restoration.

In the present series middle column SAIF was able to solve a therapeutic challenge, avoiding an invasive surgical approach. Patients were treated in a day surgery setting; they were mobilized and allowed to stand and walk the same day of the procedure. Feasibility, safety and efficacy of the SAIF technique has already been evaluated in clinical practice of extensive lytic vertebral lesions,²⁸ severe osteoporotic vertebral fractures,²⁹ and even in cases of vertebra plana²³ with durable results at follow-up; two biomechanical modeling studies provide support for this approach in both neoplastic³⁰ and osteoporotic¹⁹ conditions. In this reported series, by applying SAIF to the middle column fracture, a modified technique was undertaken, featuring a far lateral oblique trocar access to reach the central portion of the posterior third of the vertebral body, an area that is otherwise inaccessible with standard transpedicular access. In all but case 4,

a trocar was inserted parallel to the vertebral endplates, so that the radial force of the VBS could be exerted in a cranio-caudal direction as much as possible. In all cases, the deployment of the VBS in the middle column led to partial fracture reduction and height restoration. This could also be achieved in case 4 where a VBS was placed only on one side due to restricted vertebral body volume. An efficient height restoration can also provide indirect partial central canal decompression (figure 4K) exploiting the ligamentotaxis mechanism, thereby reducing the posterior wall retropulsion in some cases.¹³

In the middle column SAIF technique the metallic mesh of the VBS serves to create a scaffold that prevents the deflation effect, and maintains a cavity in the middle column, restraining bone cement leakage. The purposes of the screws in re-fracture of the middle column is threefold: to provide internal osteosynthesis of the pediculo-somatic junction, to prevent the mobilization of the stent, and, along with cement, to build a rigid bridge across the anterior, middle and posterior columns, acting as an internal fixation of the vertebra.

An additional potential advantage of SAIF over surgical repair is the lack of multilevel spinal fixation, drastically reducing the risk of hardware loosening and failure in patients with severe osteoporosis.

CONCLUSIONS

In selected cases, a middle column SAIF technique is safe and effective for the treatment of re-fracture with middle column collapse of non-SAIF previously cement-augmented vertebral compression fractures. This technique requires precision in trocar placement but could represent a useful addition to the technical armamentarium for VCF treatment.

Author affiliations

¹Department of Interventional Neuroradiology, University Hospital Centre Besancon, Besancon, France

²Pain Management Center, Neurocenter of Southern Switzerland EOC, Lugano, Switzerland

³Faculty of Biomedical Sciences, Università della Svizzera italiana Facoltà di scienze biomediche, Lugano, Switzerland

⁴Department of Radiology, Massachusetts General Hospital, Boston, Massachusetts, USA

⁵Department of Neuroradiology, Neurocenter of Southern Switzerland EOC, Lugano, Switzerland

⁶Neuroradiology Unit, Service of Diagnostic and Interventional Radiology, Sion Hospital Valais Romand Hospital Center, Sion, Switzerland

⁷Neurosurgery Department, Neurocenter of the Southern Switzerland EOC, Lugano, Switzerland

⁸Chemistry, Materials and Chemical Engineering "Giulio Natta", Politecnico di Milano, Milano, Italy

⁹IRCCS Istituto Ortopedico Galeazzi, Milano, Italy

¹⁰Department of Neuroradiology, Inselspital University Hospital Bern, Bern, Switzerland

Twitter Joshua A Hirsch @JoshuaAHirsch

Contributors AC, FDC and MP contributed to conception and design of the study and analysis of data. AC, FDC, MP and DSM prepared the figures and drafted the text. All co-authors contributed to the acquisition of data, provided significant input to interpretation of data, reviewed the paper and revised it for important intellectual content. All co-authors approved the final version to be published. AC and FDC are responsible for the overall content as guarantors. MP and AC request joint last co-authorship.

Funding The authors have not declared a specific grant for this research from any funding agency in the public, commercial or not-for-profit sectors.

Competing interests JAH received consulting fees from Medtronic, Relievant, Agnovos and Spine Biopharma. JAH is a deputy editor of JNIS.

Patient consent for publication Not applicable.

Ethics approval This study involves human participants and was approved by the Ethics Committee of Canton Ticino (ID 14-136). Participants gave informed consent

to participate in the study before taking part.

Provenance and peer review Not commissioned; externally peer reviewed.

Data availability statement All data relevant to the study are included in the article or uploaded as supplementary information.

Supplemental material This content has been supplied by the author(s). It has not been vetted by BMJ Publishing Group Limited (BMJ) and may not have been peer-reviewed. Any opinions or recommendations discussed are solely those of the author(s) and are not endorsed by BMJ. BMJ disclaims all liability and responsibility arising from any reliance placed on the content. Where the content includes any translated material, BMJ does not warrant the accuracy and reliability of the translations (including but not limited to local regulations, clinical guidelines, terminology, drug names and drug dosages), and is not responsible for any error and/or omissions arising from translation and adaptation or otherwise.

ORCID iDs

Fortunato Di Caterino <http://orcid.org/0000-0003-4478-0486>

Joshua A Hirsch <http://orcid.org/0000-0002-9594-8798>

REFERENCES

- Cianfoni A, Distefano D, Isalberti M, et al. Stent-screw-assisted internal fixation: the SAIF technique to augment severe osteoporotic and neoplastic vertebral body fractures. *J Neurointerv Surg* 2019;11:603–9.
- Berenson J, Pflugmacher R, Jarzem P, et al. Balloon kyphoplasty versus non-surgical fracture management for treatment of painful vertebral body compression fractures in patients with cancer: a multicentre, randomised controlled trial. *Lancet Oncol* 2011;12:225–35.
- Uppin AA, Hirsch JA, Centenera LV, et al. Occurrence of new vertebral body fracture after percutaneous vertebroplasty in patients with osteoporosis. *Radiology* 2003;226:119–24.
- Lin CC, Chen IH, Yu TC, et al. New symptomatic compression fracture after percutaneous vertebroplasty at the thoracolumbar junction. *AJNR Am J Neuroradiol* 2007;28:1042–5.
- Leslie-Mazwi T, Deen HG. Repeated fracture of a vertebral body after treatment with balloon kyphoplasty: case illustration. *J Neurosurg Spine* 2006;4:270.
- Chen L-H, Hsieh M-K, Liao J-C, et al. Repeated percutaneous vertebroplasty for refracture of cemented vertebrae. *Arch Orthop Trauma Surg* 2011;131:927–33.
- Nagaraja S, Awada HK, Dreher ML, et al. Effects of vertebroplasty on endplate subsidence in elderly female spines. *J Neurosurg Spine* 2015;22:273–82.
- Gan M, Zou J, Zhu X, et al. Balloon kyphoplasty for osteoporotic spinal fractures with middle column compromise. *Injury* 2014;45:1539–44.
- Chiu Y-C, Yang S-C, Chen H-S, et al. Clinical evaluation of repeat percutaneous vertebroplasty for symptomatic cemented vertebrae. *J Spinal Disord Tech* 2012;25:E245–53.
- Blatter TR, Schnake KJ, Gonschorek O, et al. Spine section of the German Society for Orthopaedics and Trauma. Nonsurgical and surgical management of osteoporotic vertebral body fractures: recommendations of the spine section of the German Society for Orthopaedics and Trauma (DGOU). *Global Spine J* 2018;8:505–5.
- Winkler EA, Yue JK, Birk H, et al. Perioperative morbidity and mortality after lumbar trauma in the elderly. *Neurosurg Focus* 2015;39:E2.
- Kobayashi N, Numaguchi Y, Fuwa S, et al. Prophylactic vertebroplasty: cement injection into non-fractured vertebral bodies during percutaneous vertebroplasty. *Acad Radiol* 2009 ;16:136–43.
- Venier A, Roccatagliata L, Isalberti M, et al. Armed kyphoplasty: an indirect central canal decompression technique in burst fractures. *AJNR Am J Neuroradiol* 2019;40:1965–72.
- Lin W-C, Lee Y-C, Lee C-H, et al. Refractures in cemented vertebrae after percutaneous vertebroplasty: a retrospective analysis. *Eur Spine J* 2008;17:592–9.
- Kang S-K, Lee CW, Park NK, et al. Predictive risk factors for refracture after percutaneous vertebroplasty. *Ann Rehabil Med* 2011;35:844–51.
- Farcy JP, Weidenbaum M, Glassman SD. Sagittal index in management of thoracolumbar burst fractures. *Spine* 1990;15:958–65.
- Tsoumakidou G, Too CW, Koch G, et al. CIRSE guidelines on percutaneous vertebral augmentation. *Cardiovasc Intervent Radiol* 2017;40:331–42.
- Cianfoni A, La Barbera L. Advanced principles of minimally invasive vertebral body stabilization in severe benign and malignant fractures: stent-screw assisted internal fixation. In: Beall DP, ed. *Vertebral augmentation. The comprehensive guide to vertebroplasty, kyphoplasty, and implant augmentation*. Stuttgart: Georg Thieme Verlag KG, 2020: 207–15.
- La Barbera L, Cianfoni A, Ferrari A, et al. Stent-screw assisted internal fixation of osteoporotic vertebrae: a comparative finite element analysis on SAIF technique. *Front Bioeng Biotechnol* 2019;7:291.
- Distefano D, Scarone P, Isalberti M, et al. The 'armed concrete' approach: stent-screw-assisted internal fixation (SAIF) reconstructs and internally fixates the most severe osteoporotic vertebral fractures. *J Neurointerv Surg* 2021;13:63–8.
- Eriksen EF. Cellular mechanisms of bone remodeling. *Rev Endocr Metab Disord* 2010;11:219–27.

- 22 Yen CH, Teng MMH, Yuan WH, *et al.* Preventive vertebroplasty for adjacent vertebral bodies: a good solution to reduce adjacent vertebral fracture after percutaneous vertebroplasty. *AJNR Am J Neuroradiol* 2012;33:826–32.
- 23 Cianfoni A, Delfanti RL, Isalberti M, *et al.* Minimally invasive stent screw-assisted internal fixation technique corrects kyphosis in osteoporotic vertebral fractures with severe collapse: a pilot "Vertebra Plana" series. *AJNR Am J Neuroradiol* 2022;43:776–83.
- 24 Nagoshi N, Fukuda K, Shioda M, *et al.* Anterior spinal fixation for recollapse of cemented vertebrae after percutaneous vertebroplasty. *BMJ Case Rep* 2016;2016:bcr2016214510.
- 25 Yang S-C, Chen W-J, Yu S-W, *et al.* Revision strategies for complications and failure of vertebroplasties. *Eur Spine J* 2008;17:982–8.
- 26 Yonezawa Y, Yonezawa N, Kanazawa Y, *et al.* Revision balloon kyphoplasty and vertebra-pediculoplasty using cannulated screws for osteoporotic vertebral fractures with cement dislodgement following conventional balloon kyphoplasty. *J Neurointerv Surg* 2022;14:844–6.
- 27 Yonezawa N, Yonezawa Y, Nishimura T, *et al.* Vertebra-pediculoplasty: a new approach to treatment of split-type and delayed-union osteoporotic vertebral fracture with a risk of cement dislodgement. *World Neurosurg* 2021;155:e55–63.
- 28 Cianfoni A, Distefano D, Scarone P, *et al.* Stent screw-assisted internal fixation (SAIF): clinical report of a novel approach to stabilizing and internally fixating vertebrae destroyed by malignancy. *J Neurosurg Spine* 2019;20:1–12.
- 29 Distefano D, Scarone P, Isalberti M, *et al.* The 'armed concrete' approach: stent-screw-assisted internal fixation (SAIF) reconstructs and internally fixates the most severe osteoporotic vertebral fractures. *J Neurointerv Surg* 2021;13:63–8.
- 30 La Barbera L, Cianfoni A, Ferrari A, *et al.* Stent screw-assisted internal fixation (SAIF) of severe lytic spinal metastases: a comparative finite element analysis of the SAIF technique. *World Neurosurg* 2019;128:e370–7.